

Molecular Detection, Characterisation and Serological Survey of Chicken Astrovirus from Broiler Flocks in Malaysia

Abdullahi Abdullahi Raji^{1,2}, Aini Ideris^{1,3}, Mohd Hair Bejo⁴ and Abdul Rahman Omar^{1,4*}

¹Laboratory of Vaccine and Biomolecules, Institute of Bioscience, Universiti Putra Malaysia, 43400 UPM, Serdang, Selangor, Malaysia

²Department of Veterinary Pathology, Faculty of Veterinary Medicine, City Campus Complex, Usmanu Danfodiyo University, 840212 Sokoto, Sokoto State, Nigeria

³Department of Veterinary Clinical Studies, Faculty of Veterinary Medicine, Universiti Putra Malaysia, 43400 UPM, Serdang, Selangor, Malaysia

⁴Department of Veterinary Pathology and Microbiology, Faculty of Veterinary Medicine, Universiti Putra Malaysia, 43400 UPM, Serdang, Selangor, Malaysia

ABSTRACT

Astroviruses have been associated with enteric and extra-intestinal disorders in many animal species, including chickens. Here, we describe the detection and characterisation of chicken astrovirus (CAstV) in broilers and its seroprevalence in broiler breeder flocks. Based on PCR protocol, viral confirmation was carried out on clinical tissue samples from broiler chickens suffering from uneven growth and poor performance. The tissues were molecularly detected for CAstV with differential diagnostic testing against the Newcastle disease virus, infectious bronchitis virus, avian nephritis virus, avian rotavirus, fowl

adenovirus and avian reovirus. Polymerase gene-based phylogenetic analyses of the twenty samples detected positive for CAstV indicate they belong to Group I and are related to strains from the US, UK, India and Poland. From these 20 samples, CAstV could be isolated from 3 samples upon inoculation in 5-day-old specific-pathogen-free (SPF) embryonated chicken eggs (ECE); virus-infected embryos showed dwarfing, haemorrhages, oedema and gelatinous lesions at harvest. The enzyme-linked immunosorbent assay (ELISA)

ARTICLE INFO

Article history:

Received: 3 October 2021

Accepted: 21 December 2021

Published: 18 March 2022

DOI: <https://doi.org/10.47836/pjst.30.2.43>

E-mail addresses:

abdullahi.raji@udusok.edu.ng (Abdullahi Abdullahi Raji)

aiini@upm.edu.my (Aini Ideris)

mdhair@upm.edu.my (Mohd Hair Bejo)

aro@upm.edu.my (Abdul Rahman Omar)

*Corresponding author

results revealed a high prevalence of antibodies against CAstV amongst the broiler breeder flocks tested. It is the first study that describes the detection and prevalence of CAstV in broiler chickens and broiler breeder flocks in Malaysia.

Keywords: Broiler breeder, broilers, chicken astrovirus, Malaysia, PCR, polymerase gene

INTRODUCTION

Enteric poultry viruses of the RNA group such as *Rotaviridae*, *Reoviridae*, *Picornaviridae*, *Astroviridae* and *Coronaviridae* are ubiquitous and could cause varying disease conditions in broiler chickens (Shah et al., 2016). The abundance of these RNA families, especially the *Astroviridae*, has been documented in both healthy and sick broilers, persisting within the ages of 2 to 6 weeks (Pantin-Jackwood et al., 2008). The *Astroviridae* family is divided into 2; the mamastrovirus, which affects mammalian species, and the avastrovirus, which affects avian species (Bosch et al. 2012). In previous studies, two astroviruses belonging to the avastrovirus, viz, avian nephritis virus (ANV) and chicken astrovirus (CAstV), have been detected and characterised (Imada et al., 2000; Baxendale & Mebatsion, 2004).

Chicken astrovirus (CAstV) shares familial characteristics with other astroviruses such as naked, small, round-shaped, positive-sense, single-stranded RNA. The genome is 7.5 kb in length and 38 nm in diameter and consists of three genes encoded in three open reading frames (Koci & Schultz-Cherry 2002; De Benedictis et al. 2011). CAstV is associated with uneven growth, runting stunting syndrome (Baxendale & Mebatsion, 2004; Kang et al., 2018), visceral gout and severe kidney disease (Bulbule et al., 2013), locomotor disorder (de Wit et al., 2011) and white chick syndrome (Sajewicz-Krukowska et al., 2016; Nuñez et al., 2020). Historically, CAstV is known to affect the broiler-type of chickens within the first few days of life, causing significant economic losses due to a decrease in feed conversion, high culling rate and reduced slaughter uniformity, with accompanying increased treatment expenses (Smyth et al., 2009). Conversely, in older chickens, especially breeders, the virus causes a temporary yet significant decrease in the hatch rate, with mid-to-late dead-in-shell embryos (Smyth, 2017).

Although establishing the impact of CAstV infections in chickens has been difficult due to the absence of assay, a wide variety of clinical manifestations and gross pathology overlap with other enteric viruses, recent advances in molecular diagnosis have eased its diagnosis. The reverse transcriptase-polymerase chain reaction (RT-PCR) is the gold standard in astrovirus diagnosis (Pérot et al., 2017). Smyth et al. (2009) developed a degenerate primer set capable of amplifying 510 base pairs (bp). The primer pair contains the 24 spacer sequence, a non-coding region between the polymerase genes' 3'-end and the beginning of *ORF-2* (capsid gene) that could detect all CAstV types (Smyth et al., 2009). The absence of a suitable serological diagnostic tool was addressed with the design of an

enzyme-linked immunosorbent assay (ELISA) kit capable of screening chicken sera for the presence of CAstV-specific antibodies (Skibinska et al., 2015). However, the indirect ELISA kit that is now commercially available can only detect antibodies against members of the Group B CAstV due to a lack of serological cross-reactivity between the capsid genes of Group A and B CAstVs (Smyth, 2017). The kit is valuable for testing breeders before or in-lay for seroconversion against group B CAstVs. Reports have shown that the ELISA kit is useful in longitudinal serosurvey and prevalence studies (Smyth, 2017).

This study described the identification, propagation, and isolation of CAstV from clinical tissue samples submitted by different commercial broiler farms in Peninsular Malaysia to the Avian Diagnostic Unit of the Laboratory of Vaccine and Biomolecules, Institute of Bioscience Universiti Putra Malaysia. Additionally, a serological survey was conducted to determine the prevalence of the virus amongst commercial broiler breeder flocks within Peninsular Malaysia.

MATERIALS AND METHODS

Sample Origin

Between January 2017 and January 2018, a total of 45 cases from different commercial broiler farms across Peninsular Malaysia with major complaints of uneven growth and poor performance were submitted to the Avian Diagnostic Unit of the Laboratory of Vaccine and Biomolecules, Institute of Bioscience, Universiti Putra Malaysia for molecular screening. History further revealed that the broilers exhibited varying illnesses and lesions on post-mortem examinations. Therefore, chicken astrovirus (CAstV) with extra-intestinal tissue tropism was proposed to cause the outbreak. Initial molecular screening (RT-PCR) with CAstV-specific primers confirmed 22 out of the 45 cases to be CAstV positive. However, an additional investigation on the 22 cases with seven other RNA and DNA enteric viruses' gene-specific primers (GSPs) confirmed 20 cases to be only CAstV positive. These 20 cases were then considered for further analysis in this study (Table 1).

Table 1
Samples details with background information

No	Sample ID	Farm Location	Age in days (D)	Clinical Case	Tissue(s) Submitted for Screening
1	IBS395/2017	Kedah	18D	Increased mortality, swollen kidney	Kidney

Table 1 (Continue)

No	Sample ID	Farm Location	Age in days (D)	Clinical Case	Tissue(s) Submitted for Screening
2	IBS404/2017	Kedah	NA	Mortality of about 1% daily for two weeks Fibrous perihepatitis, pericarditis and airsacculitis Swollen kidney, urolithiasis in dehydrated birds	Kidney and caecal tonsils
3	IBS425/2017	NA	58D	Mortality of about 1% daily Fever, swollen kidneys with moderate urate deposits	Kidney and caecal tonsils
4	IBS433/2017	Setiawan, Perak	33D	Increased mortality ~1% daily. Swollen kidney	Kidney and caecal tonsils
5	IBS468/2017	Setiawan, Perak	30D	Swollen kidney and discoloured liver	Kidney and caecal tonsils
6	IBS489/2017	NA	23D	Visceral gout, swollen kidney, enlarged and swollen gall bladder and mild gizzard erosion	Kidney and caecal tonsils
7	IBS503/2017	Kedah	30D	Mortality of 0.5-1.2% daily	Kidney and caecal tonsils
8	IBS508/2017	NA	22D	Swollen kidney with urate deposits	Kidney and caecal tonsils
9	IBS518/2017	Kedah	26D	Stunted birds and mortality Swollen kidney and enlarged gallbladder	Kidney and Caecal tonsils
10	IBS543/2017	Yong Peng, Johor	21D	Poor uniformity of the flock with somnolence and culling rate up to 1% on day 21	Proventriculus and caecal tonsils
11	IBS551/2017	Penang	29D	0.2% mortality, Ruffled feathers, Slow growth/moderate uniformity. PM: swollen kidneys; discoloured and enlarged liver	Kidney
12	IBS555/2017	Penang	24D	Runting stunting. PM: swollen kidney, airsacculitis, pericarditis, thin and loosed elastic intestine	Kidney and caecal tonsils

Table 1 (Continue)

No	Sample ID	Farm Location	Age in days (D)	Clinical Case	Tissue(s) Submitted for Screening
13	IBS574/2017	NA	24D	Pale kidney, foci necrotic liver, pale leg, runting and stunting	Kidney
14	IBS609/2017	NA	NA	NA	Caecal tonsils
15	IBS667/2017	Penang	27D	Marked enlarged kidney. Urate deposit. Increased mortality (0.5% daily)	Kidney, caecal tonsils and Proventriculus
16	IBS693/2017	NA	36D	Poor uniformity	Caecal tonsils
17	UPM713/2018	NA	34D	Poor uniformity. Decreased feed intake. PM: swollen kidney, airsacculitis, pericarditis, perihepatitis	Kidney and caecal tonsils
18	UPM1007/2018	NA	NA	NA	Intestine
19	UPM1013/2018	NA	27D	NA	Caecal Tonsils
20	UPM1019/2018	NA	23D	Swollen kidneys. Urate deposits. Visceral gout	Kidney

NA= Not applicable

Molecular Detection

Extraction of Nucleic Acids. Nucleic acids (total RNA and DNA) were extracted from the kidney, liver and intestine homogenates (after three series of freeze-thawing) where the supernatant was harvested after centrifugation of the samples in 50 ml Eppendorf tubes at 1,200 x g for 20 mins at 4°C to pellet the debris in an Eppendorf centrifuge (Eppendorf 5810R refrigerated centrifuge, Germany). The supernatant was then passed through a 0.45 µM Minisart® syringe filter (Sartorius AG, Germany). TRIzol™ Reagent (Invitrogen, California, USA) was then used based on the manufacturer's instructions for extracting DNA and RNA from the samples.

Conventional PCR and RT-PCR. Primer sets of enteric and extra-intestinal virus used in the differential diagnosis included those of the chicken astrovirus (CAstV) (Smyth et al., 2009), avian rotavirus (AvRV) (Day et al., 2007), chicken parvovirus (ChPV) (Zsak et al. 2013), avian reovirus (ARV) (Pantin-Jackwood et al., 2008), avian nephritis virus (ANV) (Day et al. 2007), infectious bronchitis virus (IB) (Adzhar et al., 1997), Newcastle

disease virus (NDV) (Pang et al., 2002) and fowl adenovirus (FAdV) (Meulemans et al., 2001). Conventional PCR and RT-PCR were carried out as described elsewhere (Day & Zsak, 2013; Smyth et al., 2009), with necessary modifications.

Extraction and Cleaning of RT-PCR Positive Amplicons. The obtained amplicons were electrophoresed at a voltage of 125 for 45 mins on a 1% agarose gel in 50X TAE Buffer (Thermo Fisher Scientific™, Lithuania). They were visualised by Midori Green Advance DNA stain (NIPPON Genetics Europe, Germany) and viewed using gel viewer GelDoc® (Bio-Rad, California, USA). The 510 bp PCR product of the partial polymerase gene (*ORF-1b*) was gel excised and purified using the ReliaPrep™ DNA Clean-Up and Concentration System (Promega, Southampton, UK). Purified amplicons were outsourced for sequencing (Macrogen Inc., Seoul, Korea).

Sequence Data and Phylogenetic Analyses. The sequences were edited and aligned using BioEdit version 7. The basic local alignment search tool (BLAST) on the National Centre for Bioinformatics Information (NCBI) site was then used to compare all 20 *ORF-1b* amino acid sequences with those of 28 other CAstV isolates sourced from the GenBank. The GenBank accession numbers of the isolates were FJ476304, FJ476309, KT886453, FJ476307, FJ476308, FJ476296, FJ476298, FJ476297, FJ476294, FJ476295, FJ476300, FJ476301, FJ476302, FJ476305, KY038163, FJ476299, FJ476292, FJ476306, FJ476293, FJ476303 (Smyth et al., 2009), JF832365 (direct submission), KX397576 (Patel et al., 2017), KX397575, KX397575 (Kang et al., 2018), JF414802 (Kang et al. 2012), MN725025, MN725026 and MK746105 (Xue et al., 2020). The trimmed sequences were then subjected to phylogenetic analysis on MEGA X. The tree was generated using the best scoring model (JTT+G) and Maximum-Likelihood (ML) with 1000 bootstrap replicates.

Propagation of the CAstV Positive Samples in SPF-ECE. All the 20 positive tissue samples were processed and blindly passaged four times by inoculation into 5-day old specific-pathogen-free (SPF) embryonated chicken eggs (ECE) via the yolk-sac route as described by Erica & Stephens (2016). Healthy SPF-ECE (Malaysian Vaccine Pharmaceuticals) were selected by candling five days post-lay, transferred into a class 2 biosafety cabinet (ESCO Class II BSC, Singapore), disinfected with ethanol on the surface and allowed to dry. A hole that penetrated the shell and egg membrane at the top of the egg in the centre of the air cell was made using an egg punch. Slowly, 0.2 ml of the homogenate suspension was inoculated using a 1cc syringe with a 22 G, 1” needle (Terumo, Philippines). The hole was then glued with wax, and eggs were placed back into the incubator and candled daily for ten days. The death of an embryo within 24 hours was considered to be non-specific. Dead embryos were chilled at 4°C before harvesting and observation of lesions.

Characterisation of Gross Lesions on the Inoculated SPF-ECE. The embryos were observed for lesions associated with viral infections such as haemorrhages, oedema, reddening of the tips of extremities of the limbs, deformities, dwarfing, gelatinous aspects on the embryo and liver discolouration.

Extraction of Viral RNA from Chicken Astrovirus Inoculated SPF-ECE. Harvested SPF embryos (whole) if embryo mortality occurred within 2 to 5 days post-inoculation (dpi) or liver and intestines if embryo mortality occurred between 8 to 10dpi were homogenised, and all other procedures were conducted as described earlier.

Molecular Detection of CAstV RNA by RT-PCR. The detection was conducted as described previously by Smyth et al. (2009), with some modifications. Briefly, primer pairs targeting the polymerase gene were used in the RT-PCR, and a reaction was carried out using Superscript IV One-Step RT-PCR System. A reaction mix comprising 12.5 µL 2 x Platinum SuperFi RT-PCR Master Mix, 0.2 µL SuperScript IV RT Mix, 2 µL of each of the RNA template, forward and reverse primers to a final concentration of 0.5 µM each, and diethylpyrocarbonate (DEPC) H₂O to a final volume of 25 µL were used. The thermal cycler (Bio-Rad C1000 Touch Thermal Cycler (Bio-Rad, California, USA) was set on the following conditions: reverse transcription at 50°C for 10 min and initial denaturation 98°C for 2 min, followed by 40 cycles of denaturation at 98°C for 10 sec, annealing for 10 sec at 65.5°C, extension 72°C for 30 sec and a final extension at 72°C for 5 min.

Serological Survey Against CAstV Antibodies

Collection of Serum Samples. A total of 420 serum samples (30 sera per house) were collected for serological screening of antibodies against CAstV from 14 breeder flocks representing four commercial broiler breeder farms in Peninsular Malaysia. The age range of the breeders was between 30 and 62 weeks age. Further details regarding history, medication, vaccination and location remain confidential. Serum samples were collected in-line with FAO protocol and stored at 4°C until the analysis.

Serological Screening Using ELISA Kit. A CAstV Group B Antibody test kit based on enzyme-linked immunosorbent assay (ELISA) (BioChek, the Netherlands) was used in determining the broiler breeder antibody titre based on the manufacturer's protocol. A microplate reader (Biotek EL800, Biotek Instruments, USA) with a 405 nm filter reader was used in reading the plates. A sample to positive (S/P) ratio above 0.70 (titre of 967) was considered positive.

RESULTS AND DISCUSSION

Enteric viruses and their associated diseases cause significant economic losses in poultry worldwide, yet knowledge about them is still lacking. Their effect on chicken and turkey production lines has been reported in several countries, indicating their widespread presence in both healthy and sick young chicks, especially those of the broiler-type and poults (Shah et al., 2016). Here, we described the identification, propagation, isolation and partial (*ORF-1b*) sequence characterisation of CAstV from tissue samples of broiler chickens suffering from different illnesses in Malaysia between January 2017 to January 2018. This study also followed these analyses with a serosurvey of four commercial broiler breeder farms in Peninsular Malaysia to ascertain the presence and extent of the spread of the virus.

Molecular screening of the total nucleic acids (DNA and RNA) extracted from the 20 tissue samples using virus-specific conventional RT-PCR and PCR assays revealed that all the 20 samples were positive for CAstV but not for other agents screened. The expected amplicon size of 510bp could be obtained from all the positive samples (Figure 1). The primers, which were designed from a conserved region (polymerase gene encoded in *ORF-1b*), contained the promoter site that aids in the synthesis of CAstV genome subgenomic RNA cleaved in the *ORF-2* capsid gene (Smyth et al., 2009), thus, enabling high degrees of specificity and sensitivity.

Amplicons from the 20 positive tissue samples were sequenced to confirm the detection of CAstV. The 20 CAstV positive samples demonstrated the similarity of 76 to 98% and 88 to 99% at the levels of nucleotide and amino acids sequences, respectively. Analysis of the

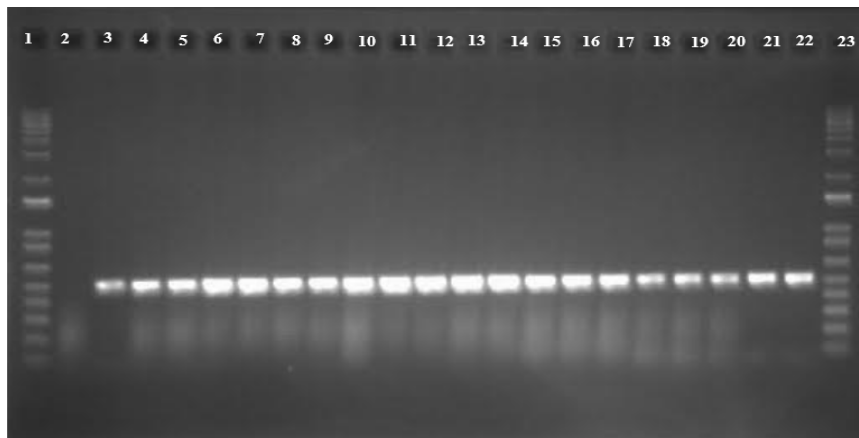


Figure 1. Amplification of CAstV specific products. Lane 1 and 23, molecular weight markers; Lane 2, negative control; Lanes 3, IBS395/2017; 4, IBS404/2017; 5, IBS425/2017; 6, IBS433/2017; 7, IBS468/2017; 8, IBS489/2017; 9, IBS503/2017; 10, IBS508/2017; 11, IBS518/2017; 12, IBS53/2017; 13, IBS551/2017; 14, IBS555/2017; 15, IBS574/2017; 16, IBS609/2017; 17, IBS667/2017; 18, IBS693/2017; 19, UPM713/2018; 20, UPM1007/2018; 21, UPM1013/2018; 22, UPM1019/2018.

453 bp nucleotide sequence of each of the 20 samples corroborated the findings of earlier reports by Pantin-Jackwood et al. (2008) and Todd et al. (2009a). Phylogenetic analysis displayed two distinct groups containing subgroups. In contrast, the first group (Group I) comprised all the Malaysian isolates and many subgroups; the second group (Group II) contained many subgroups and comprised all the three available Chinese and four of the UK isolates. Hence, the 20 CAstV sequences were sub-grouped in Group I, with isolates from the US, India, South Africa, the UK, and Germany (Figure 2), sharing an amino acid sequence similarity of 95.36 to 99.33% within the sequenced partial polymerase gene. On the other hand, the Malaysian isolates shared a similarity of 88.74 to 90.06%, with Group II CAstV consisting of isolates from the UK and China. Although this classification of CAstV based on groups I and II are no longer considered in CAstV classification, it appears from this study and a previous study by Smyth et al. (2009) that Group I CAstVs could be highly prevalent. Some observations worthy of note in this study were the absence of prior sampling and/or serological screening of the flocks as early as day 0. The 100% detection rate from the tissue samples showed that the infection could have set in at an early age. It seems likely that this infection could have been a carryover in the poultry house that was either shed by earlier broilers (horizontally acquired) or spread vertically by infected chicks. Serological evidence has shown that infections with CAstV are highly prevalent in broiler breeders and their progeny (Todd et al., 2009b).

Gross examinations of the embryos revealed haemorrhages, runting, oedema and gelatinous lesions in the initial passages, with little to no discolouration at the tips of the upper and lower extremities. Dwarfing was conspicuously observed in the fourth passage in chickens that died on 10 dpi (Figure 3). These lesions were mostly observed in IBS503/2017, IBS543/2017 and UPM1019/2018 isolates and were consistent from the first to the fourth passage compared to the remaining 17 samples. The negative control embryos were devoid of lesions through all four passages. The CAstV inocula from the tissue samples were not able to be propagated *in-vivo* in the SPF-ECE yolk sac, except for three isolates (IBS503/2017, IBS543/2017 and UPM1019/2018) out of the 20 samples screened. The choice of the yolk sac as the route for inoculation was chosen because it was a nutrient-providing centre to the chicken embryo and with a link to the embryo moments after fertilisation (Nuñez et al., 2015). Four passages in SPF-ECE also failed to amplify the CAstV up to detectable levels, which led to the conclusion that the 17 CAstV positive samples could not establish a productive infection except the three isolates. These undetectable samples were not inhibited competitively by other infective enteric viruses such as ARV, AvRV, FAdv-1 and ChPV because they were initially ruled out (based on RT-PCR and PCR screening). Similar challenges have been observed by other researchers in growing isolates of astroviruses in SPF-ECE or cell culture (Smyth et al., 2009; Chamings, 2016; Palomino-Tapia et al., 2020). Although some CAstV strains are readily

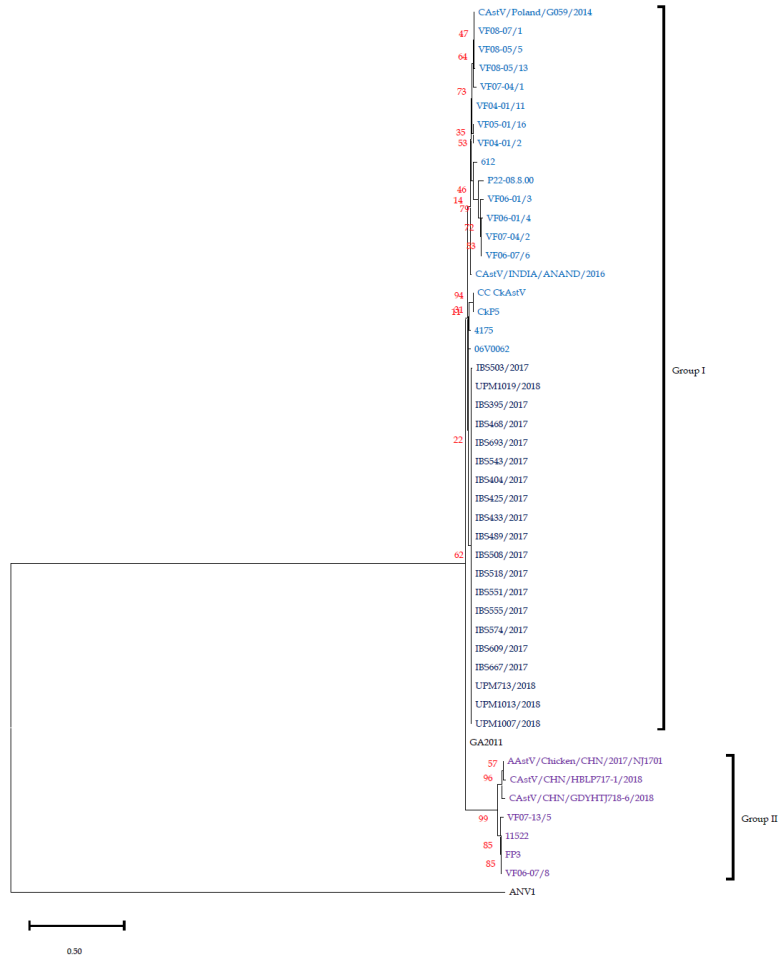


Figure 2. Phylogenetic tree of CAstV based on polymerase gene (ORF-1b) amino acid sequences. The topology is based on the maximum likelihood method, and 1000 bootstrap replicates using MEGA-X (Kumar et al., 2018). Figures on the tree are bootstrap values.

propagated in embryonic eggs or cell culture (de Wit et al., 2011; Smyth et al., 2013), the explanations for why these isolates develop while others do not is yet to be established. Strikingly, with embryo mortality observed as early as 4dpi up to 10dpi, macroscopic lesions were characterised by haemorrhages and oedematous embryo with a conspicuous dwarfing of the embryo, especially at 10 dpi (Figure 3). No characteristic lesions were observed on the embryonic membranes. This early embryo mortality pattern and lethality of the Malaysian isolates differ from earlier reports on CAstV isolates but is likely similar to turkey astrovirus (TAsTV), which produces an early lethal effect on TAsTV-inoculated embryos (Tang et al. 2006).

All the 420 serum samples were positive for CAstV specific antibodies in the serological study. Results from a one-way ANOVA indicated that the means of the antibodies were unequal, $F(13,406) = 4.798, p = .000$. Similarly, Tukey's honest significance test showed a statistically significant difference ($p < 0.05$) between the age groups. The highest antibody titres were observed at 30, 60 and 62 weeks of age, with titres of 4180 ± 1835.8 , 4248 ± 3006.5 and 4020 ± 3516.5 , respectively. As a whole, the study has presented that CAstV infection is common amongst broilers and broiler breeder flocks in Malaysia. These seropositivities in the broiler breeder flocks investigated suggest that the virus can occur in adult laying hens, consequently providing the basis of transmission from breeder hens to day-old chicks. The lower levels of seropositivity observed in some flocks tested can result from decreased virus spread on account of low replication and excretion of the virus to the environment or development of protective immunity against the virus as recorded at ages 54 to 58 weeks. Interestingly, instead of a decreased seropositivity at ages 60 and 62 weeks, an increase in titre was observed, thus suggesting that the birds were probably re-infected and not protected against the CAstV infection. The high seropositivity observed here is similar to the findings of Todd et al. (2009b) and Xue et al. (2017), where broiler parent, great-parent, and great-grandparent flocks of older ages exhibited high CAstV specific-antibody titres. Hence, in the absence of a vaccine against CAstV infection, the detection of high levels of antibodies against CAstV in the broiler breeder flocks could be actively acquired as a result of exposure to natural infection.

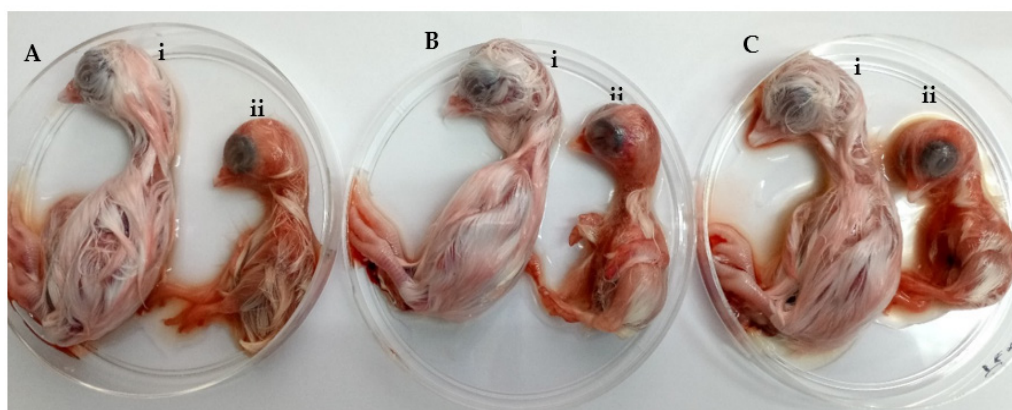


Figure 3. Fourth passages embryos at 10dpi. (A) IBS503/2017; (B) IBS543/2017 and (C) UPM1019/2018 isolates. Normal (Ai, Bi and Ci), CAstV inoculated (Aii, Bii and Cii) exhibiting clinical embryo dwarfing.

The identification of CAstV in the broiler breeder flocks demonstrates the potential challenges in eliminating the virus. As such, reports have indicated that some strains of CAstV can be transmitted vertically, with a possible pathogenic effect in chicks (Baxendale

& Mebatsion, 2004; Smyth, 2017). Consequently, SPF-ECE producers must adopt measures to eradicate CAstV in their flocks to prevent possible contamination of vaccines derived from chick embryos. In addition, serologic screening as a tool aids in demonstrating the flock's infection and its freedom from infection. Therefore, screening as described here is useful in an extensive testing exercise.

Based on the history of the birds (Table 1) and the prior identification of CAstV from tissues submitted for screening, it is clear that CAstV contributed to the clinical manifestations and lesions observed. The antibody titres recorded in this study indicates that CAstV is present in commercial broilers and broiler breeder flocks in Malaysia. The fact that this was the first study to be conducted, coupled with the lack of a vaccine against the virus, eradicating the virus may not be easy, but vaccinating the breeder flocks that will then transfer maternal antibodies (mAb) to their progeny will be necessary. Although mAb cannot fully protect chicks against CAstV, based on earlier work on ANV (Todd et al., 2009a), the first identified astrovirus in chickens, a vaccine can limit the spread of CAstV infection if developed.

In conclusion, in this study, we detected CAstV based on an RT-PCR assay and characterised the partial segment of the polymerase gene (*ORF-1b*) from 20 tissue samples of broiler-type chickens belonging to different broiler flocks suffering from varying illnesses in Peninsular Malaysia. These characterised partial polymerase genes were in Group I based on the earlier grouping of CAstV into two groups. Serological screening of broiler breeder flocks suggests high prevalent of CAstV infection based on Group B type CAstV specific ELISA. To the best of our knowledge, this is the first paper that documents the presence of CAstV in Malaysia. Further study on genome sequencing and pathogenicity is currently underway to better understand the characteristics of the CAstV strain circulating in Malaysia.

ACKNOWLEDGEMENTS

This work was supported by the Higher Institution Centre of Excellence (HICoE) [grant number 6369101]; the Ministry of Higher Education, Government of Malaysia: Geran Putra [grant number 6300212]; Universiti Putra Malaysia; and a PhD scholarship provided by Tertiary Education Trust Fund (TETFund) Nigeria Ref: TET/ES/UNI/UDFU/SOKOTO/ASTD/2017.

REFERENCES

- Adzhar, A., Gough, R. E., Haydon, D., Shaw, K., Britton, P., & Cavanagh, D. (1997). Molecular analysis of the 793/B serotype of infectious bronchitis virus in Great Britain. *Avian Pathology*, 26(3), 625-640. <https://doi.org/10.1080/03079459708419239>

- Baxendale, W., & Mebatsion, T. (2004). The isolation and characterisation of astroviruses from chickens. *Avian Pathology*, 33(3), 364-370. <https://doi.org/10.1080/0307945042000220426>
- Bosch, A., Guix, S., Krishna, N. K., Méndez, E., Monroe, S. S., Pantin-Jackwood, M., & Schultz-Cherry, S. (2012). Family-Astroviridae. In A. M. Q. King, E. Lefkowitz, M. J. Adams, & E. B. Carstens (Eds.), Ninth Report of the International Committee on Taxonomy of Viruses (pp. 953-959). Elsevier.
- Bulbule, N. R., Mandakhalikar, K. D., Kapgate, S. S., Deshmukh, V. V., Schat, K. A., & Chawak, M. M. (2013). Role of chicken astrovirus as a causative agent of gout in commercial broilers in India. *Avian Pathology*, 42(5), 464-473. <https://doi.org/10.1080/03079457.2013.828194>
- Chamings, A. (2016). *Molecular epidemiology of avian nephritis virus in commercial chicken flocks* (Doctoral dissertation). The University of Melbourne, Australia.
- Day, J. M., Spackman, E., & Pantin-Jackwood, M. (2007). A multiplex RT-PCR test for the differential identification of turkey astrovirus type 1, turkey astrovirus type 2, chicken astrovirus, avian nephritis virus, and avian rotavirus. *Avian Diseases*, 51(3), 681-684. [https://doi.org/10.1637/0005-2086\(2007\)51\[681:AMRTFT\]2.0.CO;2](https://doi.org/10.1637/0005-2086(2007)51[681:AMRTFT]2.0.CO;2)
- Day, J. M., & Zsak, L. (2013). Recent progress in the characterization of avian enteric viruses. *Avian Diseases*, 57(3), 573-580. <https://doi.org/10.1637/10390-092712-review.1>
- De Benedictis, P., Schultz-Cherry, S., Burnham, A., & Cattoli, G. (2011). Astrovirus infections in humans and animals - Molecular biology, genetic diversity, and interspecies transmissions. *Infection, Genetics and Evolution*, 11(7), 1529-1544. <https://doi.org/10.1016/j.meegid.2011.07.024>
- de Wit, J. J., ten Dam, G. B., vande Laar, J. M. A. M., Biermann, Y., Verstegen, I., Edens, F., & Schrier, C. C. (2011). Detection and characterization of a new astrovirus in chicken and turkeys with enteric and locomotion disorders. *Avian Pathology*, 40(5), 453-461. <https://doi.org/10.1080/03079457.2011.596813>
- Erica, S., & Stephens, C. (2016). Virus isolation and propagation in embryonating eggs. In S. M. Williams, L. Dufour-Zavala, M. W. Jackwood, M. D. Lee, B. Lupiani, W. M. Reed, E. Spackman, & Peter R. Woolcock. (Eds.), *A Laboratory Manual for the Isolation, Identification, and Characterization of Avian Pathogens* (sixth, pp. 361-368). OmniPress Inc.
- Imada, T., Yamaguchi, S., Mase, M., Tsukamoto, K., Kubo, M., & Morooka, A. (2000). Avian nephritis virus (anv) as a new member of the family astroviridae and construction of infectious ANV cDNA. *Journal of Virology*, 74(18), 8487-8493. <https://doi.org/10.1128/jvi.74.18.8487-8493.2000>
- Kang, K. I., Linnemann, E., Icard, A. H., Durairaj, V., Mundt, E., & Sellers, H. S. (2018). Chicken astrovirus as an aetiological agent of runting-stunting syndrome in broiler chickens. *Journal of General Virology*, 99(4), 512-524. <https://doi.org/10.1099/jgv.0.001025>
- Kang, K. I., El-Gazzar, M., Sellers, H. S., Dorea, F., Williams, S. M., Kim, T., Collett, S., & Mundt, E. (2012). Investigation into the aetiology of runting and stunting syndrome in chickens. *Avian Pathology*, 41,1, 41-50. <https://doi.org/10.1080/03079457.2011.632402>
- Koci, M. D., & Schultz-Cherry, S. (2002). Avian astroviruses. *Avian Pathology*, 9781461447(2002), 213-227. https://doi.org/10.1007/978-1-4614-4735-1_9

- Kumar, S., Stecher, G., Li, M., Knyaz, C., & Tamura, K. (2018). MEGA X: Molecular evolutionary genetics analysis across computing platforms. *Molecular Biology and Evolution*, 35(6), 1547-1549. <https://doi.org/10.1093/molbev/msy096>
- Meulemans, G., Boschmans, M., Van den Berg, T. P., & Decaesstecker, M. (2001). Polymerase chain reaction combined with restriction enzyme analysis for detection and differentiation of fowl adenoviruses. *Avian Pathology*, 30(6), 655-660. <https://doi.org/10.1080/03079450120092143>
- Núñez, L. F. N., Parra, S. H., Mettifogo, E., Catroxo, M. H., Astolfi-Ferreira, C. S., & Piantino Ferreira, A. J. (2015). Isolation of chicken astrovirus from specific pathogen-free chicken embryonated eggs. *Poultry Science*, 94(5), 947-954. <https://doi.org/http://dx.doi.org/10.3382/ps/pev086>
- Núñez, L. F. N., Santander-Parra, S. H., Kyriakidis, N. C., Astolfi-Ferreira, C. S., Buim, M. R., De la Torre, D., & Ferreira, A. J. P. (2020). Molecular characterization and determination of relative cytokine expression in naturally infected day-old chicks with chicken astrovirus associated to white chick syndrome. *Animals*, 10(7), 1-18. <https://doi.org/10.3390/ani10071195>
- Palomino-Tapia, V., Mitevski, D., Inglis, T., van der Meer, F., Martin, E., Brash, M., Provost, C., Gagnon, C. A., & Abdul-Careem, M. F. (2020). Chicken astrovirus (CAstV) molecular studies reveal evidence of multiple past recombination events in sequences originated from clinical samples of white chick syndrome (WCS) in Western Canada. *Viruses*, 12(10), Article 1096. <https://doi.org/10.3390/v12101096>
- Pang, Y., Wang, H., Girshick, T., Xie, Z., & Khan, M. I. (2002). Development and application of a multiplex polymerase chain reaction for avian respiratory agents. *Avian Diseases*, 46(3), 691-699. [https://doi.org/10.1637/0005-2086\(2002\)046\[0691:DAAOAM\]2.0.CO;2](https://doi.org/10.1637/0005-2086(2002)046[0691:DAAOAM]2.0.CO;2)
- Pantin-Jackwood, M. J., Day, J. M., Jackwood, M. W., & Spackman, E. (2008). Enteric viruses detected by molecular methods in commercial chicken and turkey flocks in the United States between 2005 and 2006. *Avian Diseases*, 52(2), 235-244. <https://doi.org/10.1637/8174-111507-Reg.1>
- Patel, A. K., Pandit, R. J., Thakkar, J. R., Hinsu, A. T., Pandey, V. C., Pal, J. K., Prajapati, K. S., Jakhesara, S. J., & Joshi, C. G. (2017). Complete genome sequence analysis of chicken astrovirus isolate from India. *Veterinary Research Communications*, 41(1), 67-75. <https://doi.org/10.1007/s11259-016-9673-6>
- Pérot, P., Lecuit, M., & Eloit, M. (2017). Astrovirus diagnostics. *Viruses*, 9(1), 1-14. <https://doi.org/10.3390/v9010010>
- Sajewicz-Krukowska, J., Pać, K., Lisowska, A., Pikuła, A., Minta, Z., Króliczewska, B., & Domańska-Blicharz, K. (2016). Astrovirus-induced “white chicks” condition - Field observation, virus detection and preliminary characterization. *Avian Pathology*, 45(1), 2-12. <https://doi.org/10.1080/03079457.2015.1114173>
- Shah, J. D., Desai, P. T., Zhang, Y., Scharber, S. K., Baller, J., Xing, Z. S., & Cardona, C. J. (2016). Development of the intestinal RNA virus community of healthy broiler chickens. *PLoS ONE*, 11(2), 1-13. <https://doi.org/10.1371/journal.pone.0150094>
- Skibinska, A., Lee, A., Wylie, M., Smyth, V. J., Welsh, M. D., & Todd, D. (2015). Development of an indirect enzyme-linked immunosorbent assay test for detecting antibodies to chicken astrovirus in chicken sera. *Avian Pathology*, 44(6), 436-442. <https://doi.org/10.1080/03079457.2015.1084411>
- Smyth, V. J. (2017). A review of the strain diversity and pathogenesis of chicken astrovirus. *Viruses*, 9(2), 1-10. <https://doi.org/10.3390/v9020029>

- Smyth, V. J., Jewhurst, H. L., Adair, B. M., & Todd, D. (2009). Detection of chicken astrovirus by reverse transcriptase-polymerase chain reaction. *Avian Pathology*, 38(4), 293-299. <https://doi.org/10.1080/03079450903055397>
- Smyth, V., Trudgett, J., Wylie, M., Jewhurst, H., Conway, B., Welsh, M., Kaukonen, E., & Perko-Mäkelä, P. (2013). Chicken astrovirus detected in hatchability problems associated with 'white chicks.' *Veterinary Record*, 173(16), 403-404. <https://doi.org/10.1136/vr.f6393>
- Tang, Y., Ismail, M. M., & Saif, Y. M. (2006). Development of antigen-capture enzyme-linked immunosorbent assay and RT-PCR for detection of turkey astroviruses. *Avian Diseases*, 49(2), 182-188. <https://doi.org/10.1637/7255-080504r>
- Todd, D., Smyth, V. J., Ball, N. W., Donnelly, B. M., Wylie, M., Knowles, N. J., & Adair, B. M. (2009a). Identification of chicken enterovirus-like viruses, duck hepatitis virus type 2 and duck hepatitis virus type 3 as astroviruses. *Avian Pathology*, 38(1), 21-29. <https://doi.org/10.1080/03079450802632056>
- Todd, D., Wilkinson, D. S., Jewhurst, H. L., Wylie, M., Gordon, A. W., & Adair, B. M. (2009b). A seroprevalence investigation of chicken astrovirus infections. *Avian Pathology*, 38(4), 301-309. <https://doi.org/10.1080/03079450903055421>
- Xue, J., Han, T., Xu, M., Zhao, J., & Zhang, G. (2017). The first serological investigation of Chicken astrovirus infection in China. *Biologicals*, 47, 22-24. <https://doi.org/10.1016/j.biologicals.2017.03.005>
- Xue, J., Han, T., Zhao, Y., Yang, H., & Zhang, G. (2020). Complete genome sequence and phylogenetic analysis of novel avastroviruses circulating in China from 2016 to 2018. *Virus Research*, 278, Article 197858. <https://doi.org/10.1016/j.virusres.2020.197858>
- Zsak, L., Cha, R. M., & Day, J. M. (2013). Chicken parvovirus-induced runting-stunting syndrome in young broilers. *Avian Diseases*, 57(1), 123-127. <https://doi.org/10.1637/10371-091212-ResNote.1>

